JACC: CARDIOVASCULAR IMAGING
VOL. 9, NO. 11, 2016

ISSN 1936-878X/$36.00
PUBLISHED BY ELSEVIER
http://dx.doi.org/10.1016/j.jcmg.2016.09.010

CMR First-Pass Perfusion for Suspected Inducible Myocardial Ischemia

Robert C. Hendel, MD,[a] Matthias G. Friedrich, MD,[b,c,d,e] Jeanette Schulz-Menger, MD,[f] Claudia Zemmrich, MD,[g] Frank Bengel, MD,[h] Daniel S. Berman, MD,[i] Paolo G. Camici, MD,[j] Scott D. Flamm, MD,[k] Dominique Le Guludec, MD, PHD,[l] Raymond Kim, MD,[m] Massimo Lombardi, MD,[n] John Mahmarian, MD,[o] Udo Sechtem, MD,[p] Eike Nagel, MD, PHD[q]

ABSTRACT

Cardiovascular magnetic resonance (CMR) has evolved from a pioneering research tool to an established noninvasive imaging method for detecting inducible myocardial perfusion deficits. In this consensus document, experts of different imaging techniques summarize the existing body of evidence regarding CMR perfusion as a viable complement to other established noninvasive tools for the assessment of perfusion and discuss the advantages and pitfalls of the technique. A rapid, standardized CMR perfusion protocol is described, which is safe, clinically feasible, and cost-effective for centers with contemporary magnetic resonance equipment. CMR perfusion can be recommended as a routine diagnostic tool to identify inducible myocardial ischemia. (J Am Coll Cardiol Img 2016;9:1338–48) © 2016 by the American College of Cardiology Foundation.

Cardiovascular disease remains a leading cause of morbidity and mortality worldwide, with coronary artery disease (CAD) being the most prevalent condition. Effective diagnosis and risk assessment are essential, and the presence and extent of myocardial ischemia, scar, and viability as well as the volumes and function of the left ventricle (LV) are key parameters in guiding care.

Recent data have demonstrated that primary angiographic assessment of patients with suspected coronary artery stenosis is often insufficient for therapeutic decision making. The detection of substantial areas of inducible ischemia is increasingly mandated to justify revascularization and provide a clinical benefit (1–4).

Cardiovascular magnetic resonance (CMR) is established as a well-validated, highly standardized technique, but still remains underutilized for ischemic heart disease for a number of reasons. Among referring cardiologists and family care physicians, CMR is perceived as a highly complex research tool of limited availability, which requires specialized

From the [a]Cardiovascular Division, University of Miami, Miller School of Medicine, Miami, Florida; [b]Departments of Medicine and Radiology, McGill University Health Centre, Montreal, Canada; [c]Department of Medicine, Heidelberg University, Heidelberg, Germany; [d]Department of Radiology, Université de Montreal, Montreal, Canada; [e]Departments of Cardiac Sciences and Radiology, University of Calgary, Calgary, Canada; [f]Charité Campus Buch, ECRC a Joint Institution of Universitätsmedizin Berlin and MDC and HELIOS Klinikum Berlin-Buch, Klinik und Poliklinik für Kardiologie und Nephrologie, Berlin, Germany; [g]Institute for Pharmacology and Preventive Medicine, Mahlow, Germany; [h]Klinik für Nuklearmedizin, Medizinische Hochschule Hannover, Hannover, Germany; [i]Cedars-Sinai Medical Center, West Hollywood, California; [j]Vita Salute University and San Raffaele Hospital, Milan, Italy; [k]Imaging, and Heart and Vascular Institutes, Cleveland Clinic, Cleveland, Ohio; [l]Department of Nuclear Medicine, Bichat Hospital, AP-HP and DHU FIRE, Paris Diderot University, INSERM U1148, Paris, France; [m]Duke Cardiovascular Magnetic Resonance Center at Duke University Medical Center, Durham, North Carolina; [n]Multimodality Cardiac Imaging Section, IRCCS Policlinico San Donato, Milan, Italy; [o]Houston Methodist Hospital, Houston, Texas; [p]Abteilung für Kardiologie, Robert-Bosch-Krankenhaus Stuttgart, Stuttgart, Germany; and the [q]Institute for Experimental and Translational Cardiovascular Imaging, University Hospital Frankfurt/Main, DZHK Centre for Cardiovascular Imaging, Frankfurt, Germany. This paper was funded by an unrestricted grant by Bayer Pharma AG. Drs. Hendel, Schulz-Menger, Zemmrich, and Nagel have received consultancy fees, attended advisory boards, and have held lectures for a number of pharmaceutical companies including Bayer HealthCare. Dr. Friedrich is a board member, advisor, and shareholder of and has received consultancy fees from Circle Cardiovascular Imaging Inc., a company that develops software for CMR image evaluation. Dr. Flamm has served as a consultant to Bayer HealthCare. Dr. Mahmarian has served on the Speakers Bureau of and as a consultant for Astellas. Dr. Nagel has received grant support from Siemens Healthcare, Bayer HealthCare, TomTec, CVI42, MEDIS, and Philips Healthcare.

Manuscript received May 31, 2016; revised manuscript received August 26, 2016, accepted September 8, 2016.

training of physicians and technicians. It is considered useful mostly for providing scientific data at high costs with long scan times rather than delivering essential clinical data with acceptable effort. In some health systems, CMR is insufficiently reimbursed or difficult to access, and there are not enough adequately trained imagers.

The basis of this paper is consensus of imaging specialists with various backgrounds. Consensus was reached by: 1) a face-to-face meeting; 2) a written proposal from the core writing group (R.H., M.F., J.S.-M., C.Z., and E.N.); and 3) iterative integration of any comment from the other authors. We summarize the existing body of evidence on the diagnostic accuracy, prognostic value, and resource- and time-effectiveness of contemporary first-pass perfusion CMR for the assessment of ischemic heart disease. We describe an efficient CMR perfusion protocol that allows guiding on subsequent patient management. Magnetic resonance (MR) coronary angiography or methods on the basis of other modalities (single-photon emission computed tomography [SPECT], positron emission tomography [PET], computed tomography perfusion, or stress echocardiography) will not be addressed in this paper. Dobutamine stress CMR will only be included as far as some of the published data does not discriminate between the 2 methods, although it is a highly attractive alternative in patients with contraindications to vasodilator stress. This review closes a knowledge gap between the guidelines and more recent evidence provided by clinical trials, and it merges these data with the extensive clinical practice within different settings reflected by a group of imaging specialists.

CMR IN CURRENT GUIDELINES

Current guidelines may not fully reflect the most recent scientific evidence on CMR due to new evidence that has been obtained since their publication.

In general, all recent guidelines provide a Class I or IIa recommendation for the use of ischemia imaging before invasive angiography in symptomatic patients with an intermediate pre-test likelihood between 15% and 85% (5-9). The choice of imaging modality (SPECT, CMR, echocardiography, or PET) is usually left to local conditions, physician or patient preference, and specific considerations.

The latest American College of Cardiology Foundation appropriate use criteria consider CMR appropriate for a large number of indications, including the diagnosis of ischemic heart disease with increasing strength at higher individual risk profiles (**Table 1**) (10).

CMR PERFUSION

SUMMARY OF CURRENT SCIENTIFIC EVIDENCE.

The evidence for the utility of perfusion CMR is considerable, including validation studies in animals against microspheres (11-13), single-center studies in selected patient populations, examination of interstudy reproducibility (14,15), and large, prospective randomized trials (16,17). CMR combines a number of favorable characteristics: 1) very good spatial resolution, allowing for the assessment of subendocardial ischemia; 2) robust image quality, independent of body habitus; 3) good temporal resolution, allowing the wash-in of the contrast agent to be visualized; 4) complementary information on LV volume, function, and morphology; and 5) tissue characterization (e.g., myocardial edema, scar, and infiltration). Additionally, CMR is not associated with ionizing radiation and possesses few contraindications and limitations, such as severe arrhythmia, severe or acute renal dysfunction, or incompatible devices (**Table 2**).

Table 3 provides a summary of the evidence from 6 large meta-analyses comparing first-pass perfusion CMR against invasive angiography. Jaarsma et al. (18) compared perfusion CMR, SPECT, and PET and found similar accuracies for CMR and PET, which were both superior to SPECT (**Figure 1**). de Jong et al. (19) compared first-pass perfusion CMR, SPECT, and stress echocardiography and found a superior accuracy of perfusion CMR versus both latter methods, which did not differ. More recently, 2 meta-analyses of noninvasive imaging versus invasive hemodynamics (fractional flow reserve) were published (20,21), and similarly demonstrated better diagnostic performance of perfusion CMR and PET versus SPECT and perfusion computed tomography (**Figure 2**).

The 2 largest studies comparing the accuracy of CMR and SPECT for the detection of CAD are MR-IMPACT II (Magnetic Resonance Imaging for Myocardial Perfusion Assessment in Coronary artery disease Trial II) (17) and CE-MARC (Clinical Evaluation of Magnetic Resonance Imaging in Coronary Heart Disease 2) (16,22). In both studies, patients were assessed with CMR, SPECT, and invasive angiography. The MR-IMPACT II trial (17) recruited 533 patients in 33 European and U.S. centers using coronary angiography as the standard of reference. Using a predefined criterion for positivity of 1 segment with "black or dark gray" appearance and neglecting all

ABBREVIATIONS AND ACRONYMS

CAD = coronary artery disease

CMR = cardiovascular magnetic resonance

LV = left ventricle

SPECT = single-photon emission computed tomography

PET = positron emission tomography

JACC: CARDIOVASCULAR IMAGING, VOL. 9, NO. 11, 2016
NOVEMBER 2016:1338–48

TABLE 1 Appropriate Use Criteria for the Use of CMR for Detection and Risk Assessment in Suspected CAD

Appropriate	*Symptomatic patients* • With at least medium to high pre-test probability of CAD and/or inability to exercise and/or a noninterpretable ECG
May be appropriate	*Symptomatic patients* • With low pre-test probability of CAD who are unable to exercise or who have an uninterpretable ECG • With intermediate pre-test probability of CAD who are able to exercise and who have an interpretable ECG *Asymptomatic individuals* • With high risk regardless of ECG interpretability and ability to exercise
Rarely appropriate	*Symptomatic patients* • With low or intermediate risk with interpretable ECG and able to exercise *Asymptomatic individuals* • With low or intermediate risk regardless of ECG interpretability and ability to exercise

Modified with permission from Wolk et al. (10)
CAD = coronary artery disease; CMR = cardiac magnetic resonance; ECG = electrocardiogram.

clinical data as well as CMR information on the basis of late gadolinium enhancement, the sensitivity of first-pass perfusion CMR to detect coronary artery stenosis was superior (0.67 vs. 0.59), whereas specificity was inferior to SPECT (0.61 vs. 0.72). The primary endpoint of the study was reached, demonstrating noninferiority of CMR versus SPECT (17). The specificity of CMR perfusion was somewhat lower than in previous publications. This was partially due to: 1) a pre-defined cutoff value, which may not have been optimal for all sequences and vendors; 2) using the "lowest common denominator" for the CMR techniques on various systems; and 3) the blinded readers having variable experience with sequences not used in their own institution. An important message to be drawn from this study is the need for on-site training using a standardized approach. The CE-MARC study (16) recruited 752 patients in a single center and found higher sensitivity, higher positive and negative predictive values, as well as better overall diagnostic accuracy of CMR when compared with SPECT. Specificity was similar for the 2 tests. In both studies, receiver-operating characteristic curve analyses showed higher values for CMR in comparison with SPECT for subgroups, such as in triple-vessel disease or in women (23).

TABLE 2 Advantages and Limitations of CMR and SPECT for Perfusion Imaging

	CMR	SPECT
Ionizing radiation	None	Yes (1–15 mSv)
Image resolution	<3 × 3 × 8 mm, cardiac coverage in 3–5 imaging planes	App 8 × 8 × 8 mm, full 3D cardiac coverage
Full LV coverage	Only with 3D	Yes
Underlying mechanism	First-pass flow of contrast agent	Cellular isotope uptake
Renal dysfunction	Not performed in patients with eGFR <30 ml/min/1.73 m^2 due to presence of a low risk of NSF Contrast agents are not nephrotoxic	No limitation
Arrhythmia	Image quality can be reduced in absolute arrhythmia or frequent PVCs (>10/min)	No limitation
Devices	Contraindicated with devices such as most ICDs and pacemakers	No limitation
Validation	Excellent validation against invasive angiography, FFR, and outcome	Excellent validation against invasive angiography, FFR, and outcome
Availability	Limited to state-of-the art centers	Widely available
Costs	Variable. In most countries relatively high	Variable. In most countries medium to high
Patient characteristics	Scanners with larger bores available for severe obesity or unfavorable body habitus	Increased risk of artifacts with obesity, risk of "balanced ischemia" in triple-vessel disease

3D = 3-dimensional; CMR = cardiac magnetic resonance; eGFR = estimated glomerular filtration rate; FFR = fractional flow reserve; ICD = implantable cardioverter-defibrillator; LV = left ventricular; NSF = nephrotic systemic fibrosis; PVC = premature ventricular complex; SPECT = single-photon emission computed tomography.

The recently presented CE-MARC II study demonstrated, in 1,202 patients with stable angina and a broad range of pre-test likelihoods, that ischemia testing with CMR perfusion imaging or SPECT imaging led to a significantly lower number of negative invasive angiographies compared with the U.K. National Institute of Clinical Excellence (NICE) guidelines, which recommend management on the basis of pre-test likelihoods (pre-test likelihood 10% to 29%: calcium-scoring; 30% to 60%: noninvasive testing; and >60%: invasive coronary angiography). Importantly, outcome (major adverse cardiovascular events) after 1 year was similar in the 3 groups (24). Further evidence is expected in the near future from another large-scale multicenter trial, which has finished recruitment and is awaiting patient outcome data (25).

PROGNOSTIC VALUE OF CMR. Several studies on vasodilator or dobutamine stress CMR have demonstrated an excellent prognostic value (26–31). The 5-year follow-up of the CE-MARC study showed that CMR, but not SPECT, added to risk stratification of patients with suspected CAD beyond classic risk factors (32). A recent meta-analysis of 19 studies (14 with vasodilatory agents, 4 with dobutamine, and 1 combined) found a higher incidence of myocardial infarction (odds ratio [OR]: 7.7), cardiovascular death (OR: 7.0), and both endpoints combined (OR: 6.5) for an abnormal stress test during a mean follow-up of 32 months. The combined outcome (annualized event) rates were 4.9% for an abnormal versus 0.8% for normal stress CMR (**Figure 3**) (33). A similar prognostic value has been demonstrated in patients with known CAD (34). More recently, Heydari et al. (35) have shown the value of

vasodilatory stress perfusion CMR for risk stratification and patients with diabetes and found a yearly event rate of 0.5% for cardiac death or myocardial infarction in patients without scar or inducible ischemia, whereas those with inducible ischemia had an event rate of 8.2% (35). In addition, there are strong data on scar imaging using late gadolinium enhancement as an independent and additional marker for outcome. This is of specific importance as ischemic scars can be found in 17% (95% confidence interval: 14% to 19%) of older patients without other signs on previous myocardial infarction in their history, echocardiogram, or electrocardiogram (36).

SAFETY OF CMR. Large registry studies in well over 30,000 patients worldwide have demonstrated the excellent safety of the CMR procedure. The EuroCMR registry enrolled more than 27,000 consecutive patients. Mild complications were detected in 994 patients (3.6%), with most events (e.g., dyspnea, chest pain, extra systoles, and so on) occurring during dobutamine or adenosine infusion. Only a total of 7 (0.026%) severe complications were encountered (2 nonsustained ventricular tachycardia and 1 ventricular fibrillation during dobutamine infusion, 2 overt heart failures, 1 unstable angina, and 1 anaphylactic shock in the setting of adenosine stress) with no deaths reported. Procedural safety was not dependent on age or sex of the patient, or on the country or center where the scan had been performed (37). A retrospective analysis of 5,782 consecutive Canadian CMR patients recorded moderate to severe complications after contrast agent administration in 9 (0.16%) contrast-enhanced studies, characterized by nausea and vomiting in 6 (0.12%) and by symptoms of an acute systemic allergic reaction in 2 (0.04%). None of the patients required hospitalization. Transient, asymptomatic atrioventricular block was not systematically recorded, but was observed in 5% of adenosine scans (38).

A study looking specifically at the safety of contrast agents found that the gadolinium chelate contrast agents are generally well-tolerated, with rare allergic reactions (0.12%) (39). In addition, gadolinium chelates cause no kidney damage at commonly used doses. However, the occurrence of nephrotic systemic fibrosis, a debilitating disease due to irreversible fibrosis of various tissues, after application of high doses of gadolinium-containing contrast agents in patients with reduced renal function have led to a more careful application of these agents. Health authorities (U.S. Food and Drug Administration and European Medicines Agency) classify contrast agents as high-risk (gadoversetamide, OptiMARK [Mallinckrodt Inc., Dublin, Ireland]; gadodiamide, Omniscan [GE Healthcare, Chicago, Illinois]; gadopentetic acid, Magnevist [Bayer Pharma AG, Berlin, Germany]), medium-risk (gadobenic acid, MultiHance [Bracco S.p.A., Milan, Italy]), or low-risk (gadoteric acid, Dotarem [Guerbet, Roissy CdG Cedex, France]; gadoteridol, Prohance [Bracco S.p.A]; gadobutrol, Gadavist [Bayer Pharma AG]), and regard the high-risk agents as contraindicated in severely reduced kidney function (estimated glomerular filtration rate <30 ml/min/1.73 m^2). The use of the more stable

TABLE 3 Diagnostic Performance of Perfusion CMR for the Detection of Significant Coronary Artery Stenosis

First Author, Year (Ref. #)	Studies, n	Sensitivity (95% CI)	Specificity (95% CI)
Nandalur et al.,* 2007 (61)	37	91 (88–94)	81 (77–85)
Hamon et al.,* 2010 (62)	26	89 (88–91)	80 (78–83)
Jaarsma et al.,* 2012 (18)	37	89 (88–91)	76 (73–78)
de Jong et al.,* 2012 (19)	28	91 (88–93)	80 (76–83)
Li et al.,* 2013 (20)	14	90 (86–93)	87 (82–90)
Takx et al.,† 2015 (21)	15	87 (84–90)	91 (89–92)
Greenwood et al.,‡ 2012 (16)	Single center	87 (82–90)	83 (80–87)
Schwitter et al.,* 2013 (17)	Multicenter	67%	61%

Data obtained from meta-analyses on a patient basis as well as from the 2 largest published studies. *At least 50% diameter stenosis in coronary angiography; †against fractional flow reserve as reference standard; ‡at least 70% (≥50% left main stem) diameter stenosis in coronary angiography.

CI = confidence interval.

FIGURE 1 Diagnostic Performance of SPECT, Perfusion CMR, and PET for Detecting Coronary Artery Disease on a Patient-Based Level

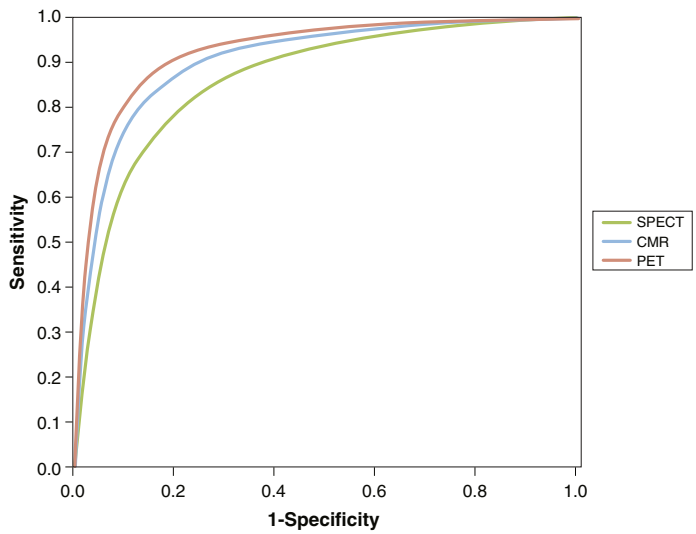

Fitted receiver-operating characteristic curves for direct comparison of single-photon emission computed tomography (SPECT) **(green)**, cardiovascular magnetic resonance (CMR) **(blue)**, and positron emission tomography (PET) **(pink)**. Reprinted with permission from Jaarsma et al. (18).

FIGURE 2 Diagnostic Accuracy of Vasodilation Perfusion CMR Compared With Invasive Coronary Angiography With Fractional Flow Reserve

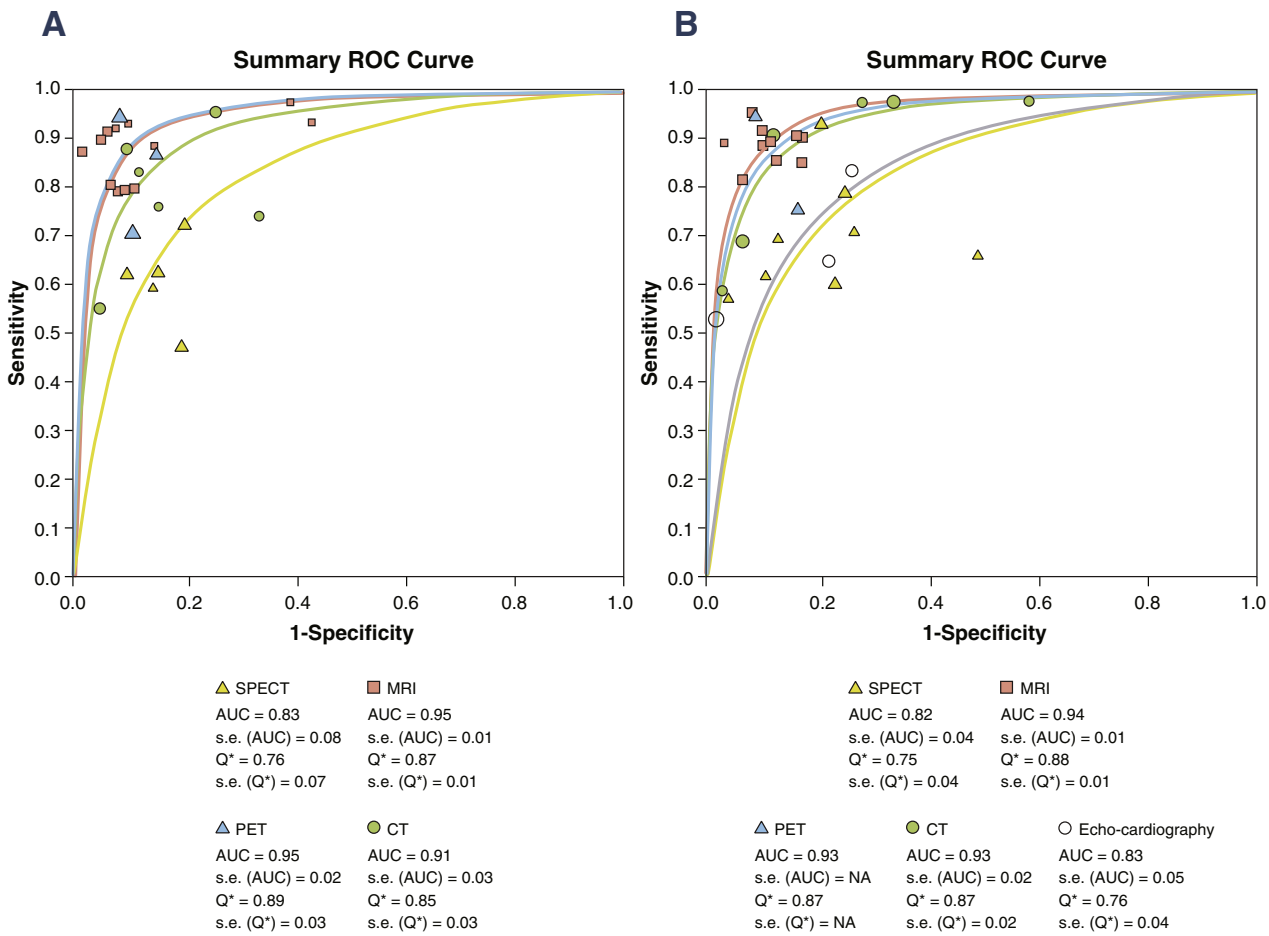

Summary receiver-operating characteristic (ROC) curve plotting the true positive rate (sensitivity) against the false-positive rate (1 − specificity) for per-vessel **(A)** and per-patient analysis **(B)**. Each **symbol** represents an individual study in the meta-analysis, with the **size of the symbol** proportional to the sample size of the study. The Q* statistic represents the point where sensitivity and specificity are equal. Reprinted with permission from Takx et al. (21). AUC = area under the summary receiver-operating characteristics curve; CT = computed tomography; MRI = magnetic resonance imaging; s.e. = standard error; other abbreviations as in Figure 1.

macrocyclic agents (Dotarem, Guerbet; or Gadavist, Bayer) is recommended in patients with reduced kidney function (estimated glomerular filtration rate <60 ml/min/1.73 m^2).

More recently, brain deposits of gadolinium in the basal ganglia have been observed after repeated (≥4) high-dose injections of gadolinium-containing contrast agents. Although this has not been linked to any harm or adverse health effects, it further supports the use of low doses of the most stable contrast agents (40). We also recommend the use of low doses for standard use (41).

Although mechanical valves pose no risk for a CMR examination, devices such as implantable cardioverter-defibrillators, cardiac resynchronization therapy, or pacemakers are still widely considered to be contraindicated. However, even in patients who underwent MR scans with such devices, complications have been very rare, and MR-safe devices are now available (42,43).

It is important to re-emphasize that CMR does not use any ionizing radiation or radioactive material, which may be preferable especially in young and in female patients.

COST-EFFECTIVENESS OF CMR. Cost effectiveness data vary enormously among various cost structures as well as various patient populations (44). In general, a higher pre-test likelihood (e.g., >83%) for the presence of significant CAD warrants the use of invasive coronary angiography (ICA) as the first test, whereas lower pre-test likelihoods are in favor of

FIGURE 3 Annualized Event Rate of Cardiovascular Death, All-Cause Mortality, or Nonfatal MI in Case of Abnormal and Normal Perfusion CMR or Positive and Negative LGE

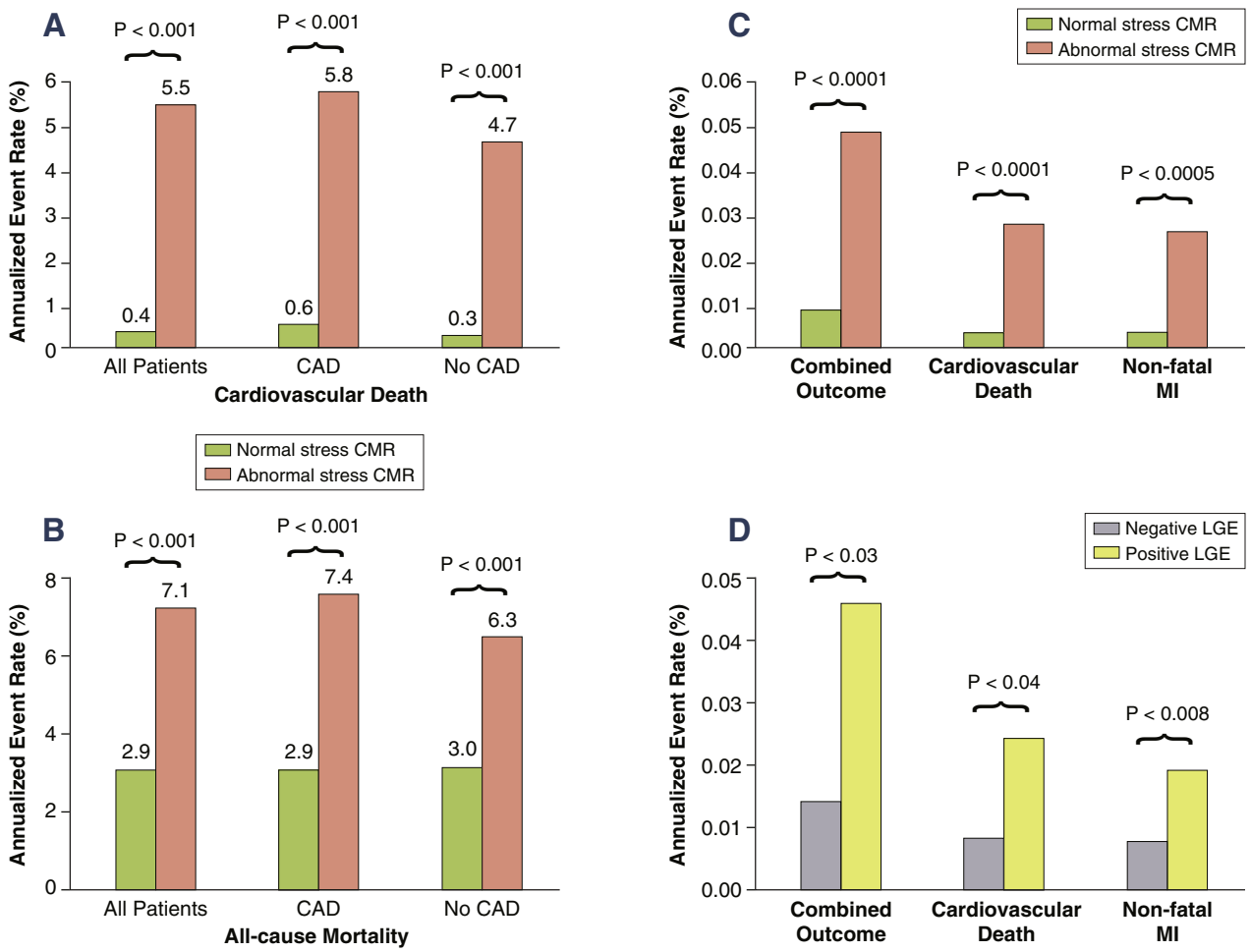

Annualized event rates are shown for **(A)** cardiovascular death, **(B)** all-cause mortality, and **(C)** nonfatal MI in abnormal and normal perfusion CMR, and for **(D)** positive and negative LGE. **(A and B)** Modified with permission from Shah et al. (34). **(C and D)** Modified with permission from Lipinski et al. (33). CAD = coronary artery disease; CMR = cardiac magnetic resonance; LGE = late gadolinium enhancement; MI = myocardial infarction.

noninvasive strategies. No explicit data are available for cost-effectiveness calculation of patient populations with low to intermediate pre-test likelihoods using CMR. However, data from intermediate to high pre-test likelihood groups support the use of CMR as a first line technique.

The European CMR registry compared the costs of a "CMR first" strategy (assessment of myocardial ischemia by CMR, followed by ICA as second step if the index CMR was positive) with an "ICA only" strategy (45). In the public sectors of the German, United Kingdom, and Swiss health care systems, cost savings from a CMR-first-driven strategy were 50%, 25%, and 23%, respectively, versus outpatient ICA. If ICA was carried out as an inpatient procedure, cost savings were 46%, 50%, and 48%, respectively. In the United States, costs were reduced by 51% when compared with inpatient ICA, but increased by 8% for CMR versus outpatient ICA (45). More recently, a calculation for "CMR first" versus ICA supported by fractional flow reserve demonstrated superior cost effectiveness for the CMR-driven strategy in groups with 62% to 83% CAD prevalence (depending on the country, highest for the United States) and equality in groups with a prevalence >83% (46).

A cost-effectiveness analysis of the CE-MARC study used a decision analytic model to compare 8 strategies for the diagnosis of CAD in outpatients referred to cardiologists for further evaluation of angina pectoris (47). Different combinations of

JACC: CARDIOVASCULAR IMAGING, VOL. 9, NO. 11, 2016
NOVEMBER 2016:1338–48

CENTRAL ILLUSTRATION Recommended CMR Protocol for Stable CAD

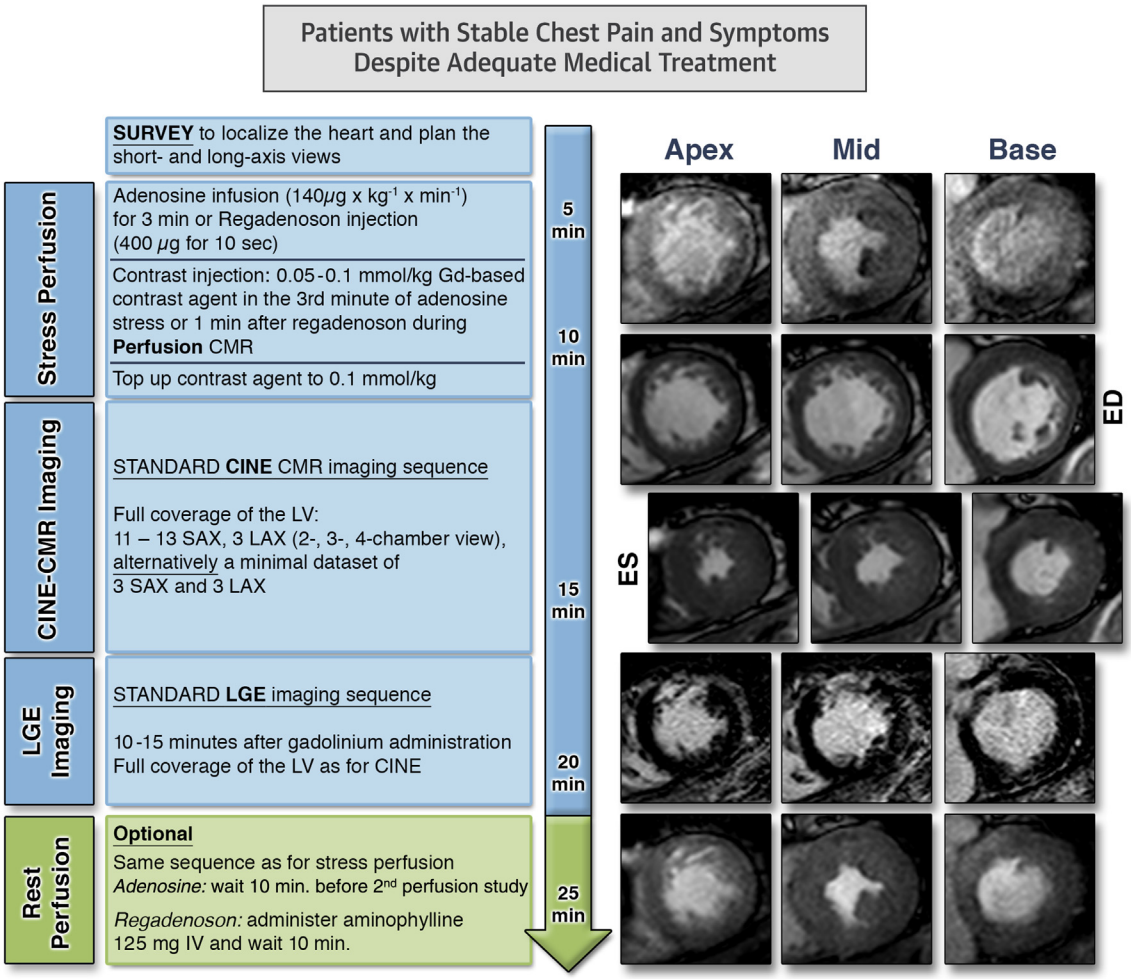

Hendel, R.C. et al. J Am Coll Cardiol Img. 2016;9(11):1338–48.

ED = end-diastolic; ES = end-systolic; Gd = gadolinium; IV = intravenous; LAX = long-axis view; LV = left ventricular; SAX = short-axis view; other abbreviations as in Figure 3.

exercise treadmill testing, SPECT, CMR, and ICA were considered. Only 2 strategies were cost-effective for the diagnosis of CAD: 1) exercise treadmill testing followed by CMR if positive or inconclusive, followed by ICA if abnormal or inconclusive; and 2) CMR followed by ICA if inconclusive. The use of SPECT was not cost-effective in this single-center study.

CMR PROCEDURES IN ISCHEMIC HEART DISEASE

PERFUSION CMR. Perfusion CMR is usually performed during pharmacological vasodilation with agents such as dipyridamole, adenosine, and, more recently, regadenoson (48). When administered intravenously, the subsequent vasodilation increases coronary blood flow approximately 2- to 4-fold. This results in visible differences between the blood flow in myocardium subtended by normal coronary arteries as opposed to coronary arteries with significant stenosis. CMR uses an intravenous bolus of an MR contrast agent, typically 0.05 to 0.1 mmol/kg body weight of a gadolinium-based agent, for detecting these flow differences. Signal intensity is related to contrast concentration, and analysis can be performed in a quantitative, semiquantitative, or qualitative fashion (49,50). Current recommendations

from the Society for Cardiovascular Magnetic Resonance recommend a qualitative assessment in clinical routine, identifying visually apparent delays and reductions of contrast inflow (51). Larger defects are prognostically more important (52). Semiquantitative analysis of the upslope of the input functions is possible and also provides clinically useful information regarding microvascular function (53).

Full quantification of CMR perfusion is becoming possible (11,54,55) but requires certain technical approaches exceeding usual routine scanning, which are not discussed in the current paper. It is of interest to note, though, that quantification of myocardial perfusion reserve for the assessment of microvascular dysfunction is increasingly demonstrating clinically important findings (56).

LATE GADOLINIUM ENHANCEMENT. In clinical practice, almost every CMR first-pass perfusion scan is followed by contrast-enhanced CMR images, typically performed 10 to 15 min after contrast injection (late gadolinium enhancement). The first pass of the contrast agent through the myocardium is used for perfusion imaging. The contrast agent then diffuses freely into the interstitial space (but remains outside of the cells), which allows demarcating areas where interstitial space is increased (e.g., scar tissue after myocardial infarction).

Scar imaging has become a standard procedure as a robust, well-validated, and accurate tool for the detection of myocardial necrosis. Even though the enhanced signal is not specific for an ischemic etiology of a scar, the regional distribution patterns of abnormal areas allow differentiation of ischemic from nonischemic injury. Ischemic scars involve the subendocardial layer and usually follow the territories defined by coronary anatomy. Scars due to myocarditis or cardiomyopathy show a distinctly different distribution pattern. Validation in animals and clinical studies demonstrate a significantly higher detection rate of subendocardial scar by CMR in comparison to SPECT imaging due to the higher spatial resolution (36).

CINE CMR IMAGING OF LV FUNCTION. Electrocardiogram-gated dynamic cine CMR sequences provide a noninvasive, accurate, and reproducible measurement of ventricular volumes, function, and regional wall motion. The heart is typically covered by a series of short- and long-axis views for volumetric and functional ventricular analysis. This may either comprise a complete short-axis stack with additional long-axis views or a combination of short- and long-axis views. Data on LV morphology, mass, volumes, and function can be acquired in 2 breath-holds (51), and modern approaches to data compression (e.g., compressed sensing) make real-time or single breath-hold 3-dimensional acquisitions a reality (57). End-diastolic or -systolic volumes, stroke volume, ejection fraction, and myocardial mass can be determined with high accuracy (58,59). Advantageous for cine CMR is the independence for any imaging windows as well as the excellent contrast between blood and myocardium for all segments, leading to excellent precision for the assessment of volumes and mass (60).

RECOMMENDED CMR PROTOCOL FOR CAD

Advances in CMR technology permit standardized short and simple protocols, resulting in time-efficient, user- and patient-friendly examinations. The protocol for the assessment of ischemic heart disease with vasodilator stress was discussed and agreed between all authors as a consensus and can be adapted for specific local environments or circumstances. It is used routinely in most of the centers of the writing group, but has only partially been scientifically explored. Further studies are required to systematically assess its value and potential for further improvement. The proposed protocol may be performed in a single 25- to 30-min session (**Central Illustration**). Dependent on local preferences, various stress agents (adenosine, dipyridamole, or regadenoson) may be used. Adenosine has a short half-life of <10 s and requires continuous infusion during the imaging procedure. The advantages of the short half-life are the brief duration of potential side effects as well as the possibility to measure function and rest perfusion soon after the stress scan, as the hemodynamic effects are rapidly reversed. Dipyridamole is less frequently used, due to its longer half-life and less reproducible vasodilation, with subsequent inferior results. Regadenoson is increasingly applied due to a longer half-life and the resulting ease of use (bolus administration, single non-weight-based dose). Regadenoson is administered intravenously 1 min before contrast injection reducing the need for infusion pumps and 2 intravenous lines. The disadvantages of the longer half-lives of dipyridamole and regadenoson are the longer persistence of side effects and the difficulty to obtain a true resting function and perfusion scan within a rapid protocol. However, with today's robust image quality and decreasing rates of artefacts, a resting perfusion scan is only required in rare cases with uncertainty about the relevance of an abnormal stress perfusion result. If required for quantification or research, the rest scan can be

JACC: CARDIOVASCULAR IMAGING, VOL. 9, NO. 11, 2016
NOVEMBER 2016:1338–48

performed before the stress scan. In this protocol the vasodilatory effects of the regadenoson can be reversed (e.g., with aminophylline), or the examination time can be prolonged to allow the stress to wean off. A physician must be available to read the stress images prior to the patient leaving the department. It should be noted that the use of all vasodilators (dipyridamole, adenosine, and regadenoson) for CMR perfusion imaging currently constitutes an off-label usage.

SUMMARY

During the last decade, CMR perfusion imaging has moved from an innovative research tool to widespread clinical applicability. However, the adoption of this technique has been largely limited to major centers, although an excellent safety profile and high diagnostic and prognostic value has been well demonstrated. CMR provides outstanding characterization of scar and ischemia, and improvements in hardware and software now enable this method to be performed in a timely and cost-efficient manner. The development of a focused, standardized protocol permits a rapid learning curve and patient-friendly examination using current scanners. Optimization of standardized CMR protocols now places this method as a potential first-line modality for the assessment of known or suspected ischemic heart disease.

REPRINT REQUESTS AND CORRESPONDENCE: Prof. Eike Nagel, Institute for Experimental and Translational Cardiovascular Imaging, DZHK Centre for Cardiovascular Imaging, University Hospital Frankfurt, 60590 Frankfurt, Germany. E-mail: eike.nagel@cardiac-imaging.org.

REFERENCES

1. Tonino PA, De Bruyne B, Pijls NH, et al. Fractional flow reserve versus angiography for guiding percutaneous coronary intervention. N Engl J Med 2009;360:213–24.

2. Boden WE, O'Rourke RA, Teo KK, et al. Optimal medical therapy with or without PCI for stable coronary disease. N Engl J Med 2007;356:1503–16.

3. Shaw LJ, Berman DS, Maron DJ, et al. Optimal medical therapy with or without percutaneous coronary intervention to reduce ischemic burden: results from the Clinical Outcomes Utilizing Revascularization and Aggressive Drug Evaluation (COURAGE) trial nuclear substudy. Circulation 2008;117:1283–91.

4. Phillips LM, Hachamovitch R, Berman DS, et al. Lessons learned from MPI and physiological testing in randomized trials of stable ischemic heart disease: COURAGE, BARI 2D, FAME, and ISCHEMIA. J Nucl Cardiol 2013;20:969–75.

5. Montalescot G, Sechtem U, Achenbach S, et al. 2013 ESC guidelines on the management of stable coronary artery disease: The Task Force of the European Society of Cardiology. Eur Heart J 2013;34:2949–3003.

6. Fihn SD, Gardin JM, Abrams J, et al. 2012 ACCF/AHA/ACP/AATS/PCNA/SCAI/STS guideline for the diagnosis and management of patients with stable ischemic heart disease: a report of the American College of Cardiology Foundation/American Heart Association Task Force on Practice Guidelines, and the American College of Physicians, American Association for Thoracic Surgery, Preventive Cardiovascular Nurses Association, Society for Cardiovascular Angiography and Interventions, and Society of Thoracic Surgeons. J Am Coll Cardiol 2012;60:e44–164.

7. Perk J, De Backer G, Gohlke H, et al. European guidelines on cardiovascular disease prevention in clinical practice (version 2012). The Fifth Joint Task Force of the European Society of Cardiology and Other Societies on Cardiovascular Disease Prevention in Clinical Practice. Eur Heart J 2012;33:1635–701.

8. NICE. Chest pain of recent onset. Clinical Guideline 95. Available at: http://www.nice.org.uk/CG95. Accessed October 13, 2016.

9. Windecker S, Kolh P, Alfonso F, et al. 2014 ESC/EACTS guidelines on myocardial revascularization. Eur Heart J 2014;35:2541–619.

10. Wolk MJ, Bailey SR, Doherty JU, et al. ACCF/AHA/ASE/ASNC/HFSA/HRS/SCAI/SCCT/SCMR/STS 2013 multimodality appropriate use criteria for the detection and risk assessment of stable ischemic heart disease. J Am Coll Cardiol 2014;63:380–406.

11. Hsu LY, Groves DW, Aletras AH, Kellman P, Arai AE. A quantitative pixel-wise measurement of myocardial blood flow by contrast-enhanced first-pass CMR perfusion imaging: microsphere validation in dogs and feasibility study in humans. J Am Coll Cardiol Img 2012;5:154–66.

12. Christian TF, Rettmann DW, Aletras AH, et al. Absolute myocardial perfusion in canines measured by using dual-bolus first-pass MR imaging. Radiology 2004;232:677–84.

13. Lee DC, Simonetti OP, Harris KR, et al. Magnetic resonance versus radionuclide pharmacological stress perfusion imaging for flow-limiting stenoses of varying severity. Circulation 2004;110:58–65.

14. Larghat AM, Maredia N, Biglands J, et al. Reproducibility of first-pass cardiovascular magnetic resonance myocardial perfusion. J Magn Reson Imaging 2013;37:865–74.

15. Elkington AG, Gatehouse PD, Ablitt NA, Yang GZ, Firmin DN, Pennell DJ. Interstudy reproducibility of quantitative perfusion cardiovascular magnetic resonance. J Cardiovasc Magn Reson 2005;7:815–22.

16. Greenwood JP, Maredia N, Younger JF, et al. Cardiovascular magnetic resonance and single-photon emission computed tomography for diagnosis of coronary heart disease (CE-MARC): a prospective trial. Lancet 2012;379:453–60.

17. Schwitter J, Wacker CM, Wilke N, et al. MR-IMPACT II: Magnetic Resonance Imaging for Myocardial Perfusion Assessment in Coronary artery disease Trial: perfusion-cardiac magnetic resonance vs. single-photon emission computed tomography for the detection of coronary artery disease: a comparative multicentre, multivendor trial. Eur Heart J 2013;34:775–81.

18. Jaarsma C, Leiner T, Bekkers SC, et al. Diagnostic performance of noninvasive myocardial perfusion imaging using single-photon emission computed tomography, cardiac magnetic resonance, and positron emission tomography imaging for the detection of obstructive coronary artery disease: a meta-analysis. J Am Coll Cardiol 2012;59:1719–28.

19. de Jong MC, Genders TS, van Geuns RJ, Moelker A, Hunink MG. Diagnostic performance of stress myocardial perfusion imaging for coronary artery disease: a systematic review and meta-analysis. Eur Radiol 2012;22:1881–95.

20. Li M, Zhou T, Yang LF, Peng ZH, Ding J, Sun G. Diagnostic accuracy of myocardial magnetic resonance perfusion to diagnose ischemic stenosis with fractional flow reserve as reference: systematic review and meta-analysis. J Am Coll Cardiol Img 2014;7:1098–105.

21. Takx RA, Blomberg BA, Aidi HE, et al. Diagnostic accuracy of stress myocardial perfusion imaging compared to invasive coronary

angiography with fractional flow reserve meta-analysis. Circ Cardiovasc Imaging 2015;8:e002666.

22. Ripley DP, Brown JM, Everett CC, et al. Rationale and design of the Clinical Evaluation of Magnetic Resonance Imaging in Coronary heart disease 2 trial (CE-MARC 2): a prospective, multicenter, randomized trial of diagnostic strategies in suspected coronary heart disease. Am Heart J 2015;169:17–24.e1.

23. Schwitter J, Wacker CM, Wilke N, et al. Superior diagnostic performance of perfusion-cardiovascular magnetic resonance versus SPECT to detect coronary artery disease: the secondary endpoints of the multicenter multivendor MR-IMPACT II (Magnetic Resonance Imaging for Myocardial Perfusion Assessment in Coronary Artery Disease Trial). J Cardiovasc Magn Reson 2012;14:61.

24. Greenwood JP, Ripley DP, Berry C, et al. Effect of care guided by cardiovascular magnetic resonance, myocardial perfusion scintigraphy, or NICE guidelines on subsequent unnecessary angiography rates: the CE-MARC 2 randomized clinical trial. JAMA 2016;316:1051–60.

25. Hussain ST, Paul M, Plein S, et al. Design and rationale of the MR-INFORM study: stress perfusion cardiovascular magnetic resonance imaging to guide the management of patients with stable coronary artery disease. J Cardiovasc Magn Reson 2012;14:65.

26. Bodi V, Sanchis J, Lopez-Lereu MP, et al. Prognostic value of dipyridamole stress cardiovascular magnetic resonance imaging in patients with known or suspected coronary artery disease. J Am Coll Cardiol 2007;50:1174–9.

27. Bodi V, Husser O, Sanchis J, et al. Prognostic implications of dipyridamole cardiac MR imaging: a prospective multicenter registry. Radiology 2012;262:91–100.

28. Pilz G, Jeske A, Klos M, et al. Prognostic value of normal adenosine-stress cardiac magnetic resonance imaging. Am J Cardiol 2008;101:1408–12.

29. Bingham SE, Hachamovitch R. Incremental prognostic significance of combined cardiac magnetic resonance imaging, adenosine stress perfusion, delayed enhancement, and left ventricular function over preimaging information for the prediction of adverse events. Circulation 2011;123:1509–18.

30. Korosoglou G, Elhmidi Y, Steen H, et al. Prognostic value of high-dose dobutamine stress magnetic resonance imaging in 1,493 consecutive patients: assessment of myocardial wall motion and perfusion. J Am Coll Cardiol 2010;56:1225–34.

31. Jahnke C, Nagel E, Gebker R, et al. Prognostic value of cardiac magnetic resonance stress tests: adenosine stress perfusion and dobutamine stress wall motion imaging. Circulation 2007;115:1769–76.

32. Greenwood J, Herzog BA, Brown JM, et al. Prognostic value of cardiovascular magnetic resonance and single-photon emission computed tomography in suspected coronary heart disease: long-term follow-up of a prospective, diagnostic accuracy cohort study. Ann Intern Med 2016 May 10 [E-pub ahead of print].

33. Lipinski MJ, McVey CM, Berger JS, Kramer CM, Salerno M. Prognostic value of stress cardiac magnetic resonance imaging in patients with known or suspected coronary artery disease: a systematic review and meta-analysis. J Am Coll Cardiol 2013;62:826–38.

34. Shah R, Heydari B, Coelho-Filho O, et al. Stress cardiac magnetic resonance imaging provides effective cardiac risk reclassification in patients with known or suspected stable coronary artery disease. Circulation 2013;128:605–14.

35. Heydari B, Juan YH, Liu H, et al. Stress perfusion cardiac magnetic resonance imaging effectively risk stratifies diabetic patients with suspected myocardial ischemia. Circ Cardiovasc Imaging 2016;9:e004136.

36. Schelbert EB, Cao JJ, Sigurdsson S, et al. Prevalence and prognosis of unrecognized myocardial infarction determined by cardiac magnetic resonance in older adults. JAMA 2012;308:890–6.

37. Bruder O, Wagner A, Lombardi M, et al. European Cardiovascular Magnetic Resonance (EuroCMR) registry—multi national results from 57 centers in 15 countries. J Cardiovasc Magn Reson 2013;15:9.

38. Luu JM, Filipchuk NG, Friedrich MG. Indications, safety and image quality of cardiovascular magnetic resonance: Experience in >5,000 North American patients. Int J Cardiol 2013;168:3807–11.

39. Bruder O, Schneider S, Pilz G, et al. 2015 update on acute adverse reactions to gadolinium based contrast agents in cardiovascular MR. Large multi-national and multi-ethnical population experience with 37788 patients from the EuroCMR Registry. J Cardiovasc Magn Reson 2015;17:58.

40. U.S. Food and Drug Administration. FDA Drug Safety Communication: FDA evaluating the risk of brain deposits with repeated use of gadolinium-based contrast agents for magnetic resonance imaging (MRI). Available at: http://www.fda.gov/Drugs/DrugSafety/ucm455386.htm. Accessed March 26, 2016.

41. Reiter T, Ritter O, Prince MR, et al. Minimizing risk of nephrogenic systemic fibrosis in cardiovascular magnetic resonance. J Cardiovasc Magn Reson 2012;14:31.

42. van der Graaf AW, Bhagirath P, Gotte MJ. MRI and cardiac implantable electronic devices; current status and required safety conditions. Neth Heart J 2014;22:269–76.

43. Roguin A, Schwitter J, Vahlhaus C, et al. Magnetic resonance imaging in individuals with cardiovascular implantable electronic devices. Europace 2008;10:336–46.

44. Francis SA, Daly C, Heydari B, Abbasi S, Shah RV, Kwong RY. Cost-effectiveness analysis for imaging techniques with a focus on cardiovascular magnetic resonance. J Cardiovasc Magn Reson 2013;15:52.

45. Moschetti K, Muzzarelli S, Pinget C, et al. Cost evaluation of cardiovascular magnetic resonance versus coronary angiography for the diagnostic work-up of coronary artery disease: application of the European Cardiovascular Magnetic Resonance registry data to the German, United Kingdom, Swiss, and United States health care systems. J Cardiovasc Magn Reson 2012;14:35.

46. Moschetti K, Favre D, Pinget C, et al. Comparative cost-effectiveness analyses of cardiovascular magnetic resonance and coronary angiography combined with fractional flow reserve for the diagnosis of coronary artery disease. J Cardiovasc Magn Reson 2014;16:13.

47. Walker S, Girardin F, McKenna C, et al. Cost-effectiveness of cardiovascular magnetic resonance in the diagnosis of coronary heart disease: an economic evaluation using data from the CE-MARC study. Heart 2013;99:873–81.

48. Abbasi SA, Heydari B, Shah RV, et al. risk stratification by regadenoson stress magnetic resonance imaging in patients with known or suspected coronary artery disease. Am J Cardiol 2014;114:1198–203.

49. Mordini FE, Haddad T, Hsu LY, et al. Diagnostic accuracy of stress perfusion CMR in comparison with quantitative coronary angiography: fully quantitative, semiquantitative, and qualitative assessment. J Am Coll Cardiol Img 2014;7:14–22.

50. Morton G, Jogiya R, Plein S, Schuster A, Chiribiri A, Nagel E. Quantitative cardiovascular magnetic resonance perfusion imaging: inter-study reproducibility. Eur Heart J Cardiovasc Imaging 2012;13:954–60.

51. Schulz-Menger J, Bluemke DA, Bremerich J, et al. Standardized image interpretation and post processing in cardiovascular magnetic resonance: Society for Cardiovascular Magnetic Resonance (SCMR) Board of Trustees Task Force on Standardized Post Processing. J Cardiovasc Magn Reson 2013;15:35.

52. Shaw LJ, Berman DS, Picard MH, et al. Comparative definitions for moderate-severe ischemia in stress nuclear, echocardiography, and magnetic resonance imaging. J Am Coll Cardiol Img 2014;7:593–604.

53. Greenwood JP, Motwani M, Maredia N, et al. Comparison of cardiovascular magnetic resonance and single-photon emission computed tomography in women with suspected coronary artery disease from the Clinical Evaluation of Magnetic Resonance Imaging in Coronary Heart Disease (CE-MARC) Trial. Circulation 2014;129:1129–38.

54. Chiribiri A, Hautvast GL, Lockie T, et al. Assessment of coronary artery stenosis severity and location: quantitative analysis of transmural perfusion gradients by high-resolution MRI versus FFR. J Am Coll Cardiol Img 2013;6:600–9.

55. Morton G, Chiribiri A, Ishida M, et al. Quantification of absolute myocardial perfusion in patients with coronary artery disease: comparison between cardiovascular magnetic resonance and positron emission tomography. J Am Coll Cardiol 2012;60:1546–55.

56. Ahn JH, Kim SM, Park SJ, et al. Coronary microvascular dysfunction as a mechanism of

JACC: CARDIOVASCULAR IMAGING, VOL. 9, NO. 11, 2016
NOVEMBER 2016:1338–48

angina in severe AS: prospective adenosine-stress CMR study. J Am Coll Cardiol 2016;67:1412–22.

57. Vincenti G, Monney P, Chaptinel J, et al. Compressed sensing single-breath-hold CMR for fast quantification of LV function, volumes, and mass. J Am Coll Cardiol Img 2014;7:882–92.

58. Armstrong AC, Gidding S, Gjesdal O, Wu C, Bluemke DA, Lima JA. LV mass assessed by echocardiography and CMR, cardiovascular outcomes, and medical practice. J Am Coll Cardiol Img 2012;5:837–48.

59. Grothues F, Moon JC, Bellenger NG, Smith GS, Klein HU, Pennell DJ. Interstudy reproducibility of right ventricular volumes, function, and mass with cardiovascular magnetic resonance. Am Heart J 2004;147:218–23.

60. Thiele H, Nagel E, Paetsch I, et al. Functional cardiac MR imaging with steady-state free precession (SSFP) significantly improves endocardial border delineation without contrast agents. J Magn Reson Imaging 2001;14:362–7.

61. Nandalur KR, Dwamena BA, Choudhri AF, Nandalur MR, Carlos RC. Diagnostic performance of stress cardiac magnetic resonance imaging in the detection of coronary artery disease: a meta-analysis. J Am Coll Cardiol 2007;50:1343–53.

62. Hamon M, Fau G, Nee G, Ehtisham J, Morello R, Hamon M. Meta-analysis of the diagnostic performance of stress perfusion cardiovascular magnetic resonance for detection of coronary artery disease. J Cardiovasc Magn Reson 2010;12:29.

KEY WORDS cardiac MRI, diagnosis, ischemic heart disease